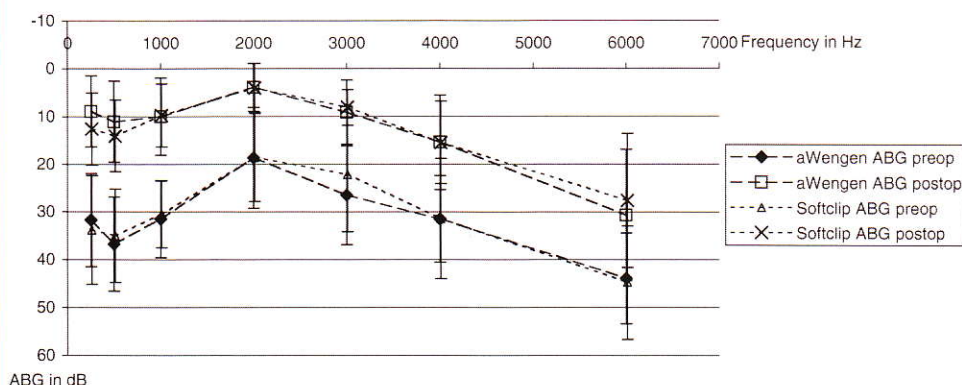



THE Laryngoscope

FOUNDED IN 1896



■ Asymptomatic Primary Hyperparathyroidism

■ 100 Years of Frontal Sinusitis

■ Facial Nerve Monitoring

■ Nasal Polyposis and Chronic Rhinosinusitis

THE AMERICAN LARYNGOLOGICAL, RHINOLOGICAL
AND OTOLOGICAL SOCIETY, INC.
The Triological Society



WILEY-BLACKWELL

Official Journal of the American
Laryngological Association

First Experience With a New Titanium Clip Stapes Prosthesis and a Comparison With the Earlier Model Used in Stapes Surgery

Joachim A. Hornung, MD; Christoph Brase, MD; Alessandro Bozzato, MD; Johannes Zenk, MD;
Heinrich Iro, MD

Objectives/Hypothesis: The aim of the study was to gain the first clinical experience with a new titanium clip prosthesis in stapes surgery, and to compare this model with its predecessor. We placed particular emphasis on the practicability of fixing the prosthesis to the long process of the incus and on the postoperative improvement in hearing.

Study Design: Retrospective chart review.

Methods: The study included 23 patients who had a CliP[®] Piston àWengen fitted and 21 patients with a Soft CliP[®] Piston (both from Kurz Medizintechnik, Dusslingen, Germany). Air and bone conduction were tested preoperatively and 5 to 6 weeks after surgery in all patients, as well as after about 1 year in a subgroup.

Results: We found a mean air-bone gap of 8.5 ± 5.2 dB in the frequencies 0.5, 1, 2, and 3 kHz for the patients with a CliP[®] Piston àWengen at follow-up audiometry after an average of 31 days, and of 6.4 ± 3.7 dB for 11 patients after 412 days. The corresponding figures for patients with Soft CliP[®] Pistons were 8.9 ± 4.1 dB after 44 days, and 6.3 ± 5.6 dB for 10 patients after 419 days. There were no statistically significant differences. All the prostheses were implanted without difficulty.

Conclusions: The two stapes prostheses studied gave good early audiometric results that showed no difference. After a short learning period, both could be pushed onto the long process of the incus with similar ease, although subjectively the new design of the Soft CliP[®] seemed to adapt better to the different

diameters of the process and took up less space in the middle ear.

Key Words: Otosclerosis, stapes surgery, clip piston, crimping.

Laryngoscope, 119:2421–2427, 2009

INTRODUCTION

Right from the time when Shea first introduced modern stapes surgery in 1956, the procedure rapidly developed a high success rate. In experienced hands, little or no residual air-bone gap (the difference between air and bone conduction) has in the meantime become the standard.

Over the years, many modifications of the surgical technique have constantly refined stapes surgery. For example, the stapedectomy originally performed was first modified to a partial stapedectomy and later to stapedotomy. With the introduction of more advanced appliances, the technique of stapes fenestration also moved on from manual perforators to microdrills and lasers. But, on the other hand, Shea's original stapedectomy technique is still successfully used today.

Apart from the changes in the surgical technique, the prostheses themselves have also undergone considerable modification. Prostheses currently used in stapes surgery differ in form, the diameter of the piston, the length of the implant, and also in weight. Fluoroplastic (Teflon[®]) is the material used most often for prostheses, but stainless steel, platinum, and titanium are also employed. Good postoperative results are achieved with a very wide range of prosthetic designs.

Apart from ease of handling during the operation, the most important requirements for a stapes prosthesis are good biocompatibility and adequate transmission of sound. Stable fixation of the prosthesis on the long process of the incus is particularly relevant to this last requirement to achieve the main objective of stapes surgery and provide a reliable and long-lasting improvement in hearing. The fixation necessary for most prostheses, referred to as crimping, is certainly one of the most difficult and, at the same time, most important

From the Department of Otorhinolaryngology, Head and Neck Surgery, University of Erlangen–Nuremberg, Friedrich Alexander University Medical School, Erlangen, Germany.

Editor's Note: This Manuscript was accepted for publication June 17, 2009.

This work was done at the Department of Otorhinolaryngology, Head and Neck Surgery, University of Erlangen–Nuremberg, Friedrich Alexander University Medical School, Erlangen, Germany.

Send correspondence to Joachim A. Hornung, MD, Department of Otorhinolaryngology, Head and Neck Surgery, University of Erlangen–Nuremberg, FAU Medical School, Waldstrasse 1, 91054 Erlangen, Germany. E-mail: joachim.hornung@uk-erlangen.de

DOI: 10.1002/lary.20641

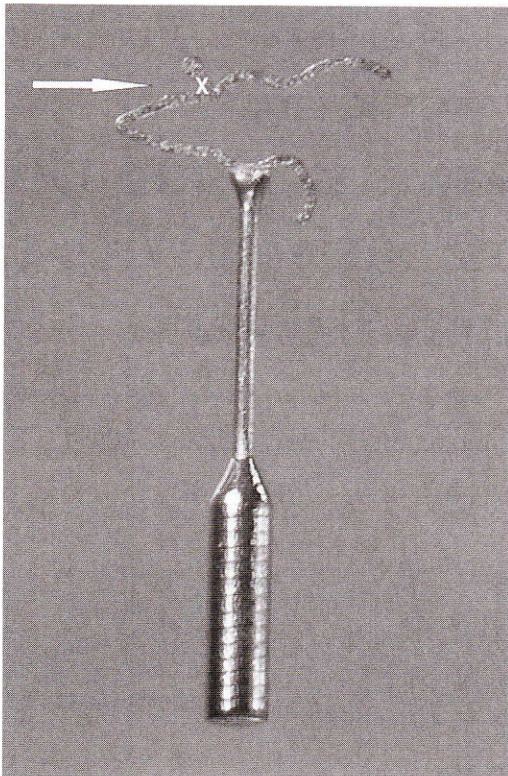


Fig. 1. CliP® Piston àWengen (Kurz Medizintechnik, Dusslingen, Germany) 4.75 × 0.6 mm. The arrow indicates the position (marked with an X) to apply the hook for clicking the prosthesis onto the long process of the incus.

steps for the quality of hearing after stapes surgery. This step is affected by a range of factors, such as the shape and thickness of the long process of the incus, the material used, the form of the prosthesis loop, the instrument used to fix the prosthesis and, last but not least, the surgeon's experience.¹ This means that, with respect to the hearing improvement and long-term stability, the results cannot be accurately predicted.

The right amount of force has to be used in crimping the loop properly. If crimping during the operation is

too loose, the prosthesis may shift in position, which in turn may lead to deterioration in hearing.² On the other hand, crimping too tightly may cause reduced perfusion of the long process of the incus with subsequent erosion and necrosis, which also results in the loss of hearing.³ To avoid the problems of fixation, various further modifications have been made to the prosthesis. One possible improvement was proposed by Daniel àWengen. Together with Kurz Medizintechnik, in Dusslingen, Germany, he developed a novel prosthesis made of titanium; this prosthesis no longer has to be crimped but is held in place on the long process of the incus by means of a specially designed clip.

Fixation is achieved by the specially shaped wire loop and the elasticity of titanium. To fix the prosthesis onto the long process of the incus, the clip is first laid on the process and then pushed into position using, for example, a tiny hook (Fig. 1, Fig. 2A, and Fig. 2B). Further fixation is not necessary. àWengen, who first inserted the new prosthesis in the year 2000, claimed several advantages for his device.^{4,5} The improved design means that the clip does not completely encircle the long process of the incus, but covers it only for about 60% of its circumference. This should promise less risk of strangulation of the long process of the incus, which in turn reduces the likelihood of bone necrosis. According to àWengen, further advantages are the reduced time taken for surgery, thanks to the easier application of the prosthesis, and better acoustic coupling because of the stable fixation of the head of the prosthesis.

In contrast, Schimanski reported that during the insertion of 275 àWengen CliP® prostheses, he had difficulties in 14.5% of cases because the diameter of the incus was either too big or too small to fix the àWengen prosthesis correctly.⁶ This led to further development of the àWengen prosthesis and the introduction of the Soft CliP® Piston (Kurz Medizintechnik, Dusslingen, Germany) with an optimized shape of the head of the prosthesis.

As the new clip is less rigid, less force should be needed to push the clip onto the long process of the incus. The head of the new prosthesis should adapt

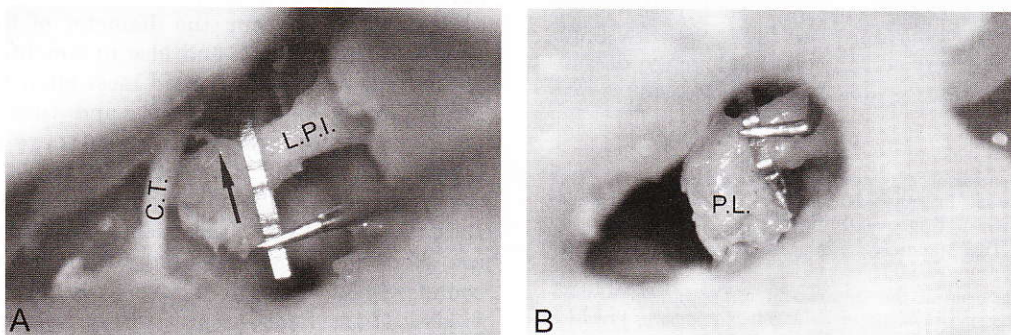


Fig. 2. Left stapedotomy with a CliP® Piston àWengen (Kurz Medizintechnik, Dusslingen, Germany) in a cadaver dissection of a temporal bone. (A) View through the auditory canal showing the prosthesis in position before it is pushed onto the incus using a straight 90° hook, 1-mm long (Storz, Tuttlingen, Germany). (B) View through a posterior tympanotomy showing the prosthesis after it has been pushed into place. The arrow indicates the direction in which the prosthesis has to be pushed onto the long process of the incus. C.T. = chorda tympani; L.P.I. = long process of the incus; P.L. = lenticular process.

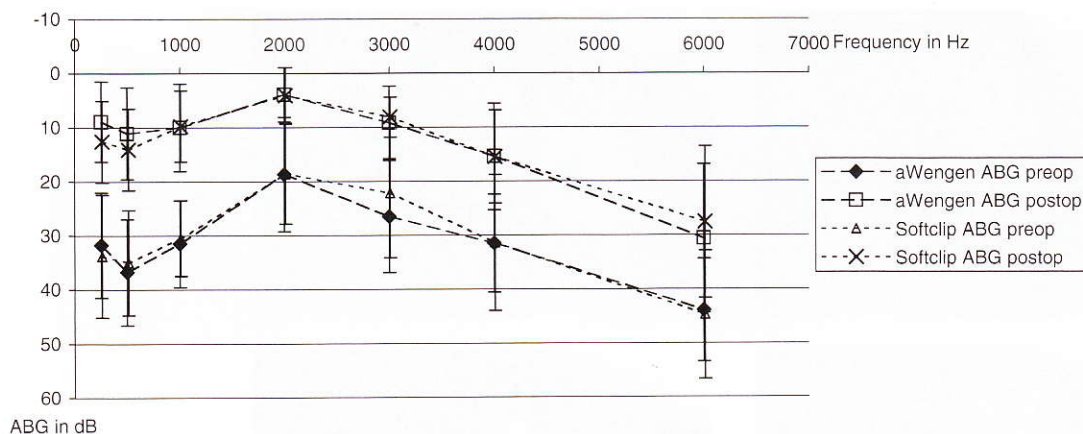


Fig. 3. Air-bone gap (ABG) comparison of the prostheses. The mean differences between air and bone conduction, the air-bone gap (ABG) (y axis in dB), based on the frequencies (x axis in Hz) measured in preoperative and postoperative audiograms in the short follow-up, are shown in dB for the Clip[®] Piston àWengen (Kurz Medizintechnik, Dusslingen, Germany) and the Soft Clip[®] Piston (Kurz Medizintechnik) (Error indicator in y axis: \pm standard deviation in dB).

better to the different shapes of the incus and reduce the risk of erosion as there is less application of force in the contact with the bone.⁶

The aim of this study was to report the first clinical experience with this new prosthesis and compare the device with its predecessor. We placed particular emphasis on the practicability of fixing the prosthesis on the long process of the incus and on the postoperative improvement in hearing.

MATERIALS AND METHODS

Between July 2007 and August 2008, the first of all 25 patients were fitted with a Clip[®] Piston àWengen (Kurz Medizintechnik), and then a further 25 patients had a Soft Clip[®] Piston (Kurz Medizintechnik) implanted. These prostheses will be referred to in the rest of this paper as W Clips and Soft Clips, respectively. However, only those patients who were undergoing primary stapes surgery were included in the study presented here (23 patients with a W Clip, 21 patients with a Soft Clip). Revision operations were not taken into account.

Both the W Clip and the Soft Clip piston had a diameter of 0.4 mm. The length of the prosthesis varied between 4.25 mm and 5.5 mm in the two groups, with prosthesis lengths of 4.5 mm and 4.75 mm being the most commonly used. The 23 patients with a W Clip were eight men and 15 women with a mean age of 46.9 ± 12.9 years (range, 23.3–68.2). The prosthesis was implanted in the right ear in 11 cases, and in the left ear in 12 cases. Soft Clips were implanted in 11 men and 10 women, with a mean age of 43.1 ± 13.9 years (range, 14.5–63.6); nine of them were fitted in the right middle ear and 12 in the left. All procedures used an endaural approach, and surgery was performed under general anaesthetic in all except three cases. One W Clip and two Soft Clips were inserted in the three operations done under regional anesthesia. We performed a stapedotomy in 21 cases in the W Clip group and in 20 of the Soft Clip group. There was one partial stapedectomy in each group, and one full stapedectomy in the W Clip group. Perforation of the stapes footplate was carried out with a laser (Type 40C; Lumenis, Tel Aviv, Israel with Acuspot 712 micromanipulator) 19 times in the W Clip and 17 times in the Soft Clip group; we used manual perforators four times in each group.

On average, the patients with a W Clip had follow-up audiometry 31.1 ± 26.4 days (range, 14–88) postoperatively, and the patients with a Soft Clip after 44.6 ± 30.4 days (range, 12–77).

So far, we have been able to re-examine 11 of the 23 patients with a W Clip piston after a mean of 412 ± 43 days (range, 373–523 days), and 10 out of the 21 patients in the Soft Clip piston group after 419 ± 68 days (range, 359–539 days).

Investigations were carried out at frequencies of 0.25, 0.5, 1, 2, 3, and 4 kHz; these results were compared with tests carried out on the day before operation. In accordance with the 1994 guidelines of the Committee on Hearing and Equilibrium, American Academy of Otolaryngology–Head and Neck Surgery Foundation Inc., the success of surgery was assessed by comparing the preoperative difference in air and bone conduction, the air-bone gap (ABG), with the corresponding postoperative values. The mean value of the ABG3000 was obtained from the frequencies 500, 1,000, 2,000 and 3,000 Hz.⁷ In addition, so that we could compare our results with those of other teams, the frequencies 500, 1,000, 2,000 and 4,000 Hz were used to calculate the ABG4000.

Relevant data were entered into the computer, stored and analyzed using Microsoft Office Professional 2003 software (Microsoft Corp., Redmond, WA) and Systat 12.0 (Systat Software Inc., Chicago, IL).

The study was conducted in accordance with the ethical standards of the 1964 Declaration of Helsinki. After in-depth explanation, the patients gave their informed consent to the operation and the evaluation of the results.

RESULTS

Comparison of the two study groups showed no statistical differences in characteristics of age, sex, follow-up period, operated ear, length of prosthesis used, surgical technique, or method of perforation.

Postoperative recovery was uneventful in both groups. There were no infections, the prostheses were well tolerated, and there was no sensorineural hearing loss or vertigo. In all cases, the clinical diagnosis of stapes fixation was confirmed at operation.

The mean ABG on the day before the operation for all patients in the W Clip group was 28.4 ± 7.7 dB. The Soft Clip group had an ABG of 26.5 ± 7.3 dB, which was statistically not significantly different. Likewise, no

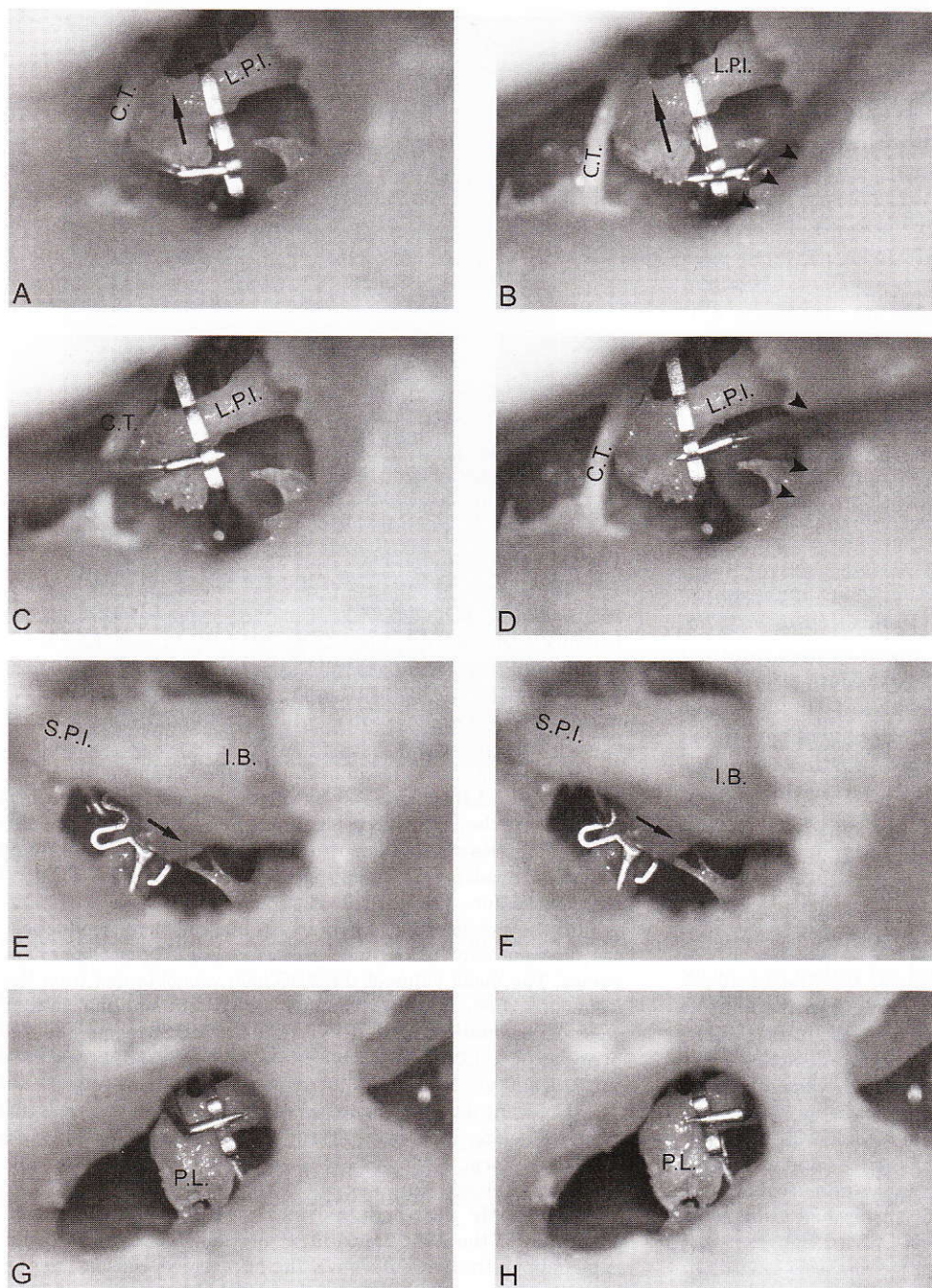


Fig. 4. Left stapedotomy with a Soft Clip® Piston (Kurz Medizintechnik, Dusslingen, Germany) in a cadaver dissection of a temporal bone. A, C, E, and G shown for a left-handed surgeon; B, D, F, and H shown for a right-handed surgeon. (A-D) View through the auditory canal. (E and F) View through a hole in the roof of the petrous part of temporal bone. (G and H) View through a posterior tympanotomy. A straight 90° hook, 1-mm long, was used to make the position of the hook clear when pushing the prosthesis into position. The arrow indicates the direction in which the prosthesis has to be pushed onto the long process of the incus; the arrowheads mark where pushing the prosthesis into place with a straight hook is hindered by the bony posterior canal wall. C.T. = chorda tympani; L.P.I. = long process of the incus; S.P.I. = short process of the incus; I.B. = incus body; P.L. = lenticular process.

statistically significant difference was found between the ABG4000 of the two groups, which were 29.6 ± 7.5 dB and 28.9 ± 7.5 dB, respectively. We determined a mean ABG of 8.5 ± 5.2 dB for the W Clip patients after an average follow-up period of 31.1 ± 26.4 days, and of 8.9 ± 4.1 dB for the patients in the Soft Clip group after 44.6 ± 30.4 days. The corresponding values for the ABG4000 were 10.1 ± 5.3 dB and 10.8 ± 4.7 dB, respectively. These were also not significantly different. All patients had an ABG <20 dB. The ABG was better than 10 dB in 60.9% ($n = 14$) of the W Clip group and in 52.3% ($n = 11$) of the Soft Clip group (Fig. 3).

The preoperative mean of bone conduction for frequencies of 1, 2, and 4 KHz was 28.0 ± 11.0 dB in the W

Clip group and 26.7 ± 14.0 dB in the Soft Clip group. The corresponding postoperative values, 27.9 ± 13.1 and 27.4 ± 13.9 dB, were more or less unchanged; the mean differences in bone conduction (-0.07 ± 5.0 dB for the group with W Clips and 0.64 ± 3.5 dB for those with Soft Clip pistons) were therefore very slight.

For the 11 patients in the W Clip group followed up again after about 1 year, we determined an ABG3000 of 6.4 ± 3.7 dB and an ABG4000 of 7.2 ± 4.0 dB. The corresponding figures for 10 patients from the Soft Clip group were 6.3 ± 5.6 dB and 7.5 ± 6.2 dB, respectively. The mean bone conduction of 1, 2, and 4 KHz frequencies was 24.1 ± 10.9 dB in the W Clip group and 26.5 ± 12.3 dB in the Soft Clip group. All patients had an ABG of <20 dB.

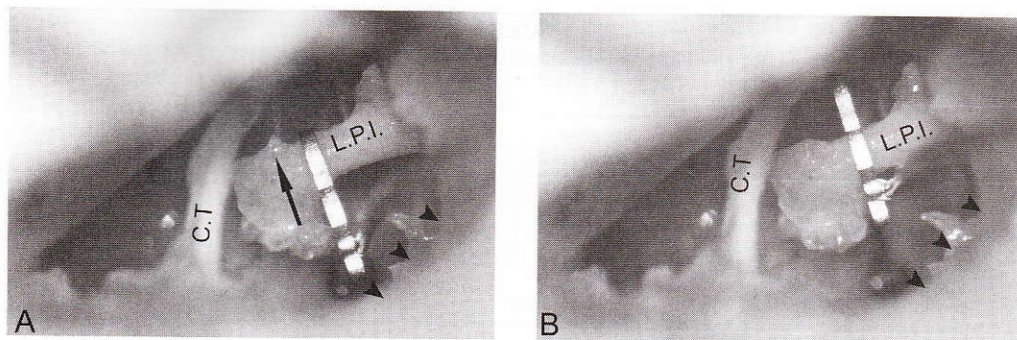


Fig. 5. Left stapedotomy with a Soft Clip® Piston (Kurz Medizintechnik, Dusslingen, Germany) in a cadaver dissection of a temporal bone. View through the auditory canal. (A) The prosthesis before it is pushed onto the incus using a Fisch footplate hook, tip angled upward 90° (Storz, Tuttlingen, Germany). (B) The prosthesis after it has been pushed into place. The arrow indicates the direction in which the prosthesis has to be pushed onto the long process of the incus; the arrowheads mark the bony posterior canal wall. C.T. = chorda tympani; L.P.I. = long process of the incus.

The ABG was better than 10 dB in nine of the 11 patients (81.8%) in the W Clip group. This was also the case in eight out of the 10 patients (80%) in the Soft Clip group. The two groups were not significantly different.

On the day of the postoperative follow-up, all patients had unremarkable findings on microscopy of the operated ear. None of the patients complained of vertigo, and all of them were satisfied with the outcome of the operation.

In all cases, the prosthesis could be fixed to the long process of the incus at operation. The prostheses were pushed into position using a straight 90° hook, or a Fisch footplate hook, with the tip angled upward 90° (Storz, Tuttlingen, Germany) as shown in Figure 2, Figure 4, and Figure 5.

DISCUSSION

In stapes surgery, many different types of prosthesis with different designs and mechanisms of fixation to the long process of the incus have been used to replace the stapes. Most of these prostheses have one characteristic in common, a loop that has to be crimped onto the long process of the incus. If this loop is closed too tightly, it may lead to a perfusion disorder of the long process of the incus with subsequent bone erosion or even necrosis. Necrosis of the long process of the incus is one of the most common reasons for revision surgery.⁸ McGee and Lesinski reported, however, that a loop that was too loose could also lead to notching of the bone with sequelae of erosion and necrosis, therefore, they recommended firm fixation of the prosthesis.^{2,3} In order to achieve a better connection, Kwok et al. proposed the use of prostheses with a band-like wire loop, as this could be more easily bent around the long process, and the wider band would allow improved pressure distribution over the mucosa in this area.¹ In short, however, crimping the wire loop around the long process of the incus remains one of the most difficult steps in stapes surgery, and the result is difficult to predict.

To avoid the difficult step of crimping, àWengen developed a stapes implant together with Kurz Medizintechnik. This prosthesis has only to be pushed onto the

long process of the incus, where it holds in position thanks to the elastic properties of titanium.⁵ àWengen reported that the first prosthesis of this type was implanted in September 2000.

As manual crimping is no longer necessary, stapes surgery using this new prosthesis should be easier and quicker. In contrast to the prostheses used previously, which when crimped completely encloses part of the long process of the incus, the new design does not cover the full circumference but only about 60% of it.⁵ This should protect the mucosa to a greater extent, with an associated improvement in the perfusion of the long process.

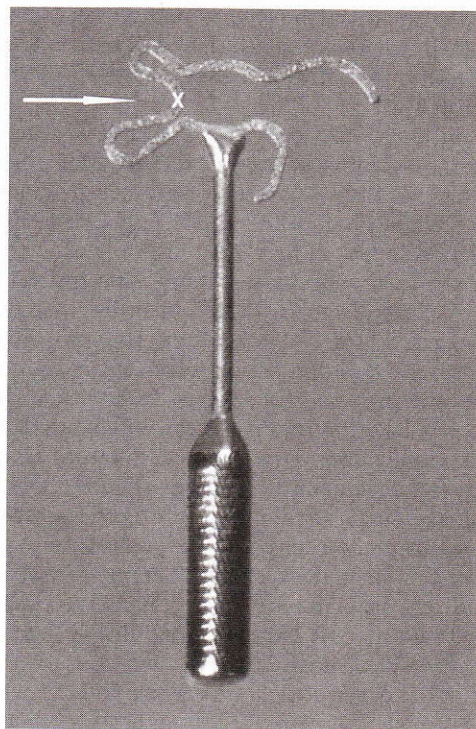


Fig. 6. Soft Clip® Piston (Kurz Medizintechnik, Dusslingen, Germany) 4.75 × 0.6 mm. The arrow indicates the position (marked with an X) to apply the hook for clicking the prosthesis onto the long process of the incus.

TABLE I.
Operating Time for the Prosthesis Used and the Side Operated On.

	Left Side		Right Side		Statistical Comparison of Sides (t test)
	n	Operating Time \pm SD (min)	n	Operating Time \pm SD (min)	
W Clip piston	12	53.58 \pm 21.96	11	50.64 \pm 22.02	NS
Soft Clip piston	12	54.75 \pm 21.23	9	49.00 \pm 17.28	NS
Statistical comparison of prostheses (t test)		NS		NS	

SD = standard deviation; NS = not significant.

In the meantime, this prototype has been used successfully by several surgical teams.⁹⁻¹² Hearing outcomes are comparable with the results of standard prostheses, but not significantly better. Even though the advertising brochures claim that the fixation process is simple, it still needs some practice, for example, with training in the temporal bone lab.⁹ A further problem of the prosthesis design is that fixation may be extremely difficult if the diameter of the long process of the incus is too large or too small.^{6,11} In particular, Schimanski reported that in 275 stapes operations with a W Clip prosthesis, he had problems with fixation in 14.5% of cases. In 13.5% the long process of the incus was too thick, and in 1.1% it was too thin. If the process is too thick, the force required to click the prosthesis into position may be so great that there is a danger of incus luxation. If the process is too thin, the prosthesis lies too loosely in contact with the bone, and this results in a poor audiological outcome.⁶ A further criticism of the clip design was the protruding head of the prosthesis, as it can make positioning of the prosthesis in the middle ear difficult.¹¹

Because of these criticisms, Schimanski, Steinhardt, and Eiber, working together with Kurz Medizintechnik, further modified the α Wengen prosthesis to produce the Soft Clip[®] Piston⁶ (shown in Fig. 4, Fig. 5, and Fig. 6).

The developers of this prosthesis reported that they had wanted to set particularly high expectations on several points in the new design.⁶ In order to reduce the risk of bone erosion, the head of the prosthesis was designed in a way intended to decrease the contact force with the long process of the incus. In addition, they had wanted to reduce the rigidity of the clip, so that it would fit more readily onto processes of different diameters. And last, the development team mentioned that the new design of the head should facilitate intraoperative handling, as the prosthesis could be pushed onto the long process of the incus more easily.⁶ Schimanski et al. demonstrated this last property in a laboratory experiment, showing that the Soft Clip required 45% less force than the W Clip to push it into place.⁶

Unlike the surgical team led by Bast,¹³ who were unable to push the Soft Clip prosthesis over the long process of the incus in two out of 11 patients, we have not yet had any cases where we were unable to fix the prosthesis and achieve good bone contact. The Soft Clip seems easier to adapt to a somewhat thicker long pro-

cess of the incus. Thanks to the new design the head protrudes less and takes up less space in the middle ear.

The differences in design mean that the procedure for pushing the prosthesis into place on the long process of the incus is also somewhat different. Common to both prostheses is that right-handers approach with the tool from the right side (see Fig. 4B, D, F, and H showing a Soft Clip prosthesis), whereas left-handers come from the left (Fig. 4A, C, E and G). With a W Clip piston, the tool is applied to a nipple on the head of the prosthesis (Fig. 1, marked with an X, and Fig. 2A and B). We used a straight 90° hook for this procedure, and were able to reach the nipple easily in all cases.

In contrast, in order to click the Soft Clip piston onto the long process of the incus, the hook has to be placed between the upper and lower loops of the prosthesis (see Fig. 6, marked with an X, and Fig. 4 and Fig. 5). This was more difficult than the procedure with the W Clip piston, as applying a straight hook is sometimes greatly hindered by the bony posterior canal wall (see arrowhead on Fig. 4B and D). This is the case when a right-handed surgeon operates on the left ear, and when a left-handed surgeon operates on the right ear. Instead of a straight hook, therefore, we employed a Fisch foot-plate hook, tip angled upward 90° (Storz), which is curved close to the tip. Contact with the bony posterior canal wall could then easily be avoided (Fig. 5A and B: the arrowheads mark the bony posterior canal wall). This tool facilitated pushing the prosthesis into place, in both the right and left ears.

Because of the initial difficulty in finding the right tool to push the prosthesis into place, we gained the subjective impression that the learning curve for positioning the Soft Clip was somewhat longer than for the W Clip piston. Objectively, however, this was not confirmed by the operating times recorded, as there was no significant difference. Operating time was 52.17 \pm 21.54 minutes for the W Clip and 52.29 \pm 19.39 minutes for the Soft Clip. Irrespective of the type of prosthesis implanted, there was only a very small time difference between the operations on the left side (54.17 \pm 21.13 minutes) and on the right side (49.9 \pm 19.5 minutes), and this was not statistically significant (see Table I).

We were unable to subjectively confirm the 45% reduction in the force required to push the Soft Clip piston into place, as reported by the developers.⁶

The postoperative audiological outcome is, of course, of particular interest when considering a new middle ear prosthesis. In this respect we found no difference between the two prostheses (see Fig. 3). Our early audiological results for both the Soft Clip and the W Clip were in the same audiometric range as those measured by other surgical teams.^{9-11,13}

At the present time, we are using the new clip design in our department. We have found that, after a little practice, both the W Clip and the Soft Clip pistons can be quickly and securely fixed to the long process of the incus. There is no need for the difficult crimping step. Making a direct comparison between the two clip prostheses, we prefer the Soft Clip piston, because it seems to be easier to adapt to the long process of the incus at operation and takes up less space in the middle ear. We believe that the special design of these two prostheses ensures better perfusion of the long process of the incus in the long term and this, in turn, means that better long-term results can be expected. Whether this is really the case will not become known until the long-term results from a large patient population are available.

CONCLUSION

After a short learning curve, both the CliP[®] Piston àWengen and the Soft CliP[®] Piston could be fixed by merely clicking the prosthesis onto the long process of the incus. Classic crimping is no longer necessary for either of these designs. The good hearing results measured audiometrically for the two pistons were not significantly different and correlate well with the findings of other surgical teams. The lesser force needing to be applied and the lesser rigidity of the Soft CliP[®] Piston loop found in vitro were not confirmed subjectively in vivo. Nevertheless, we had the impression that the Soft CliP[®] fitted the different processes of the incus better, and that the head of the prosthesis took up less space in the middle ear. Whether the modified design of the Soft CliP[®] Piston has further long-term advantages over the CliP[®] Piston àWengen, especially with respect to the fit

of the prosthesis head on the process of the incus, needs to be determined in a large-scale study and re-evaluated after follow-up for several years.

BIBLIOGRAPHY

1. Kwok P, Fisch U, Strutz J, May J. Stapes surgery: how precisely do different prostheses attach to the long process of the incus with different instruments and different surgeons? *Otol Neurotol* 2002;23:289-295.
2. McGee TM. The loose wire syndrome. *Laryngoscope* 1981; 91:1478-1483.
3. Lesinski SG. Causes of conductive hearing loss after stapedectomy or stapedotomy: a prospective study of 279 consecutive surgical revisions. *Otol Neurotol* 2002;23: 281-288.
4. Wengen DF. A new self-retaining titanium-gold stapes prosthesis [in German]. *Schweiz Med Wochenschr Suppl* 2000;116:83S-86S.
5. Wengen DF. A new self-retaining titanium clip stapes prosthesis. *Adv Otorhinolaryngol* 2007;65:184-189.
6. Schimanski G, Steinhardt U, Eiber A. Development of a new Clip-piston prosthesis for the stapes. In: Huber A, Eiber A, eds. *Middle Ear Mechanics in Research and Otology*. Singapore: World Scientific Publishing Co; 2007:237-245.
7. Committee on Hearing and Equilibrium. Guidelines for the evaluation of results of treatment of conductive hearing loss. American Academy of Otolaryngology-Head and Neck Surgery Foundation, Inc. *Otolaryngol Head Neck Surg* 1995;113:186-187.
8. Farrior J, Sutherland A. Revision stapes surgery. *Laryngoscope* 1991;101:1155-1161.
9. Grolman W, Tange RA. First experience with a new stapes clip piston in stapedotomy. *Otol Neurotol* 2005;26: 595-598.
10. Tange RA, Grolman W. An analysis of the air-bone gap closure obtained by a crimping and a non-crimping titanium stapes prosthesis in otosclerosis. *Auris Nasus Larynx* 2008;35:181-184.
11. Mangham CA Jr. Titanium CliP piston versus platinum-ribbon Teflon piston: piston and fenestra size affect air-bone gap. *Otol Neurotol* 2008;29:8-12.
12. Mangham CA Jr, Neel J, Mangham HF. Success of five stapes prostheses evaluated by Kaplan-Meier product-survival procedure. *Otol Neurotol* 2008;29:900-904.
13. Bast F, Schrom T. First experiences with the new soft-clip piston as an alloplastic prosthesis during stapedotomy [in German]. *Laryngorhinootologie* 2009;88:304-308.